

MRI Procedure

- Standard as with any MRI with/without contrast
- Men with contraindication to gadolinium can still undergo non-contrast MRI mpMRI
- If patient has been recently biopsied, six-week interval post-biopsy is optimal for mpMRI
- Endorectal coil is not necessary for the exam

Patient Prep

- No sexual activity 48 hours prior (facilitates assessment of seminal vesicles)
- No caffeine 24 hours prior (reduces bowel motion)
- Nothing to eat or drink four to six hours prior (if diabetic, patients may have their normal meals)
- Recent PSA levels, prior biopsy reports, and prior outside MRI studies if available
- Take one gas-eliminating pill (i.e., GAS-X) the evening before your exam and another the morning of the exam

CPT CODES

- 72197 (with and without contrast-gado)
- 76377 (for 3-D post-processing)



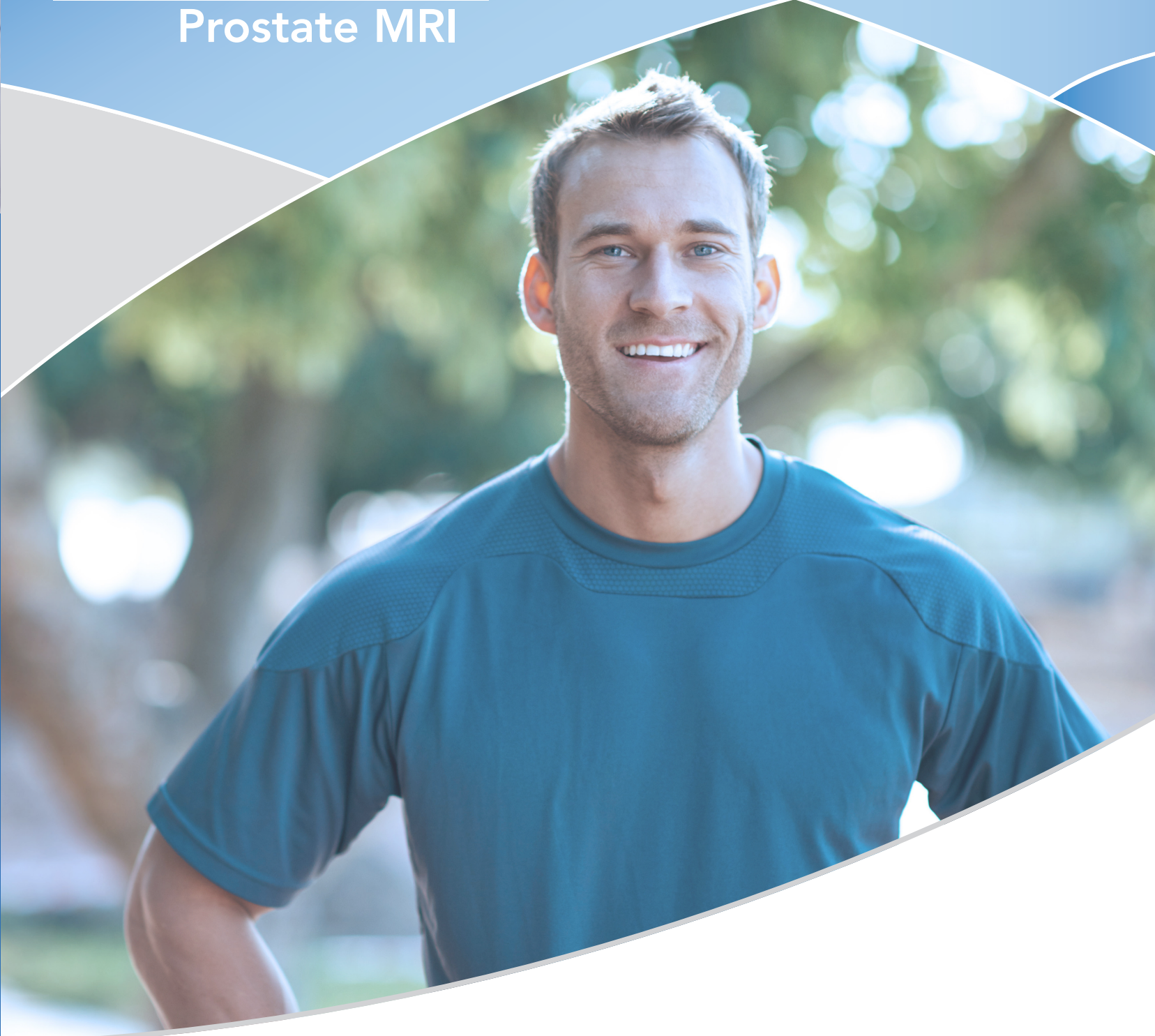To schedule your patient’s multi-parametric prostate MRI scan, please call us at
1.800.258.4674.

Shields locations below offer prostate MRI services:

BOSTON (2 locations)
BROCKTON
DARTMOUTH
FRAMINGHAM
LOWELL
NEWBURYPORT
SPRINGFIELD
WEYMOUTH
WOBURN
WORCESTER
YARMOUTH



MULTI-PARAMETRIC
Prostate MRI



BENEFITS OF Multi-Parametric Prostate MRI

Multi-parametric prostate MRI (mpMRI) greatly improves the accuracy of the diagnosis and management of prostate cancer. Until now, MRI for the prostate has been solely dependent on T2 hypointensity for tumor detection, which has low specificity with false positive and false negative results. mpMRI combines diffusion-weighted imaging, dynamic-contrast enhanced (DCE) imaging and T2 imaging to achieve greatly improved detection of lesions and localization.

ACCURATE
POWERFUL
TARGETED



WHY SHIELDS for multi-parametric prostate MRI?

Shields has been a long-time leader in prostate MRI beginning in 1992, and has been an early adopter with extensive mpMRI experience since 2011. Shields' radiologists have extensive experience in mpMRI interpretation, working closely with urologists and radiation oncologists, biopsy planning and lesion segmentation. Shields radiologists are represented on the ACR Committee for Prostate MRI Accreditation.

Indications for prostate MRI:

- Elevated or rising PSA with negative biopsy
- Elevated PSA prior to biopsy
- Verification of appropriateness for active surveillance following low-grade disease on biopsy by screening for higher-grade lesions that may not have been sampled at biopsy
- Tumor staging
- Detection of recurrent disease

Early detection of prostate cancer.

mpMRI allows for targeted biopsy that increases biopsy yield and creates a more accurate sampling of pathology, ultimately aiding in the early detection of significant prostate cancer. It is particularly beneficial in detecting tumors when used as a subsequent screening test in patients with rising PSA and prior negative biopsy.

Improving the accuracy of biopsy.

Sophisticated fusion technology combines ultrasound with MRI to improve pre-biopsy localization. The inclusion of mpMRI not only detects more significant cancers but also avoids biopsy of insignificant cancers.

Planning surgery and radiotherapy.

By clearly defining tumor location, multi-parametric MRI allows more accurate tumor staging, which helps physicians decide whether radiation or surgery is the appropriate therapy.

Monitoring patients on active surveillance.

Since tumors can be more accurately localized, mpMRI can monitor tumors after initial diagnosis.

Focal ablative therapy.

The accurate pre-biopsy localization from mpMRI makes possible focal ablative therapies that directly target the tumor.

PI-RADS reporting.

Each lesion is assigned a score of 1 to 5 for T2 and diffusion sequences, and +/- for contrast enhancement.

An overall composite score from 1 to 5 is then generated from all 3 parameters.

PI-RADS v2 score: probability that mpMRI findings for each lesion correlate with the presence of a clinically significant cancer.

PI-RADS 1: very low (clinically significant cancer is highly unlikely to be present).

PI-RADS 2: low (clinically significant cancer is unlikely to be present).

PI-RADS 3: intermediate (the presence of clinically significant cancer is equivocal).

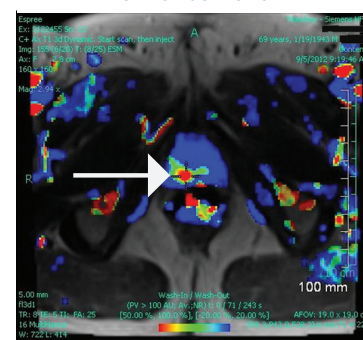
PI-RADS 4: high (clinically significant cancer is likely to be present).

PI-RADS 5: very high (clinically significant cancer is highly likely to be present).

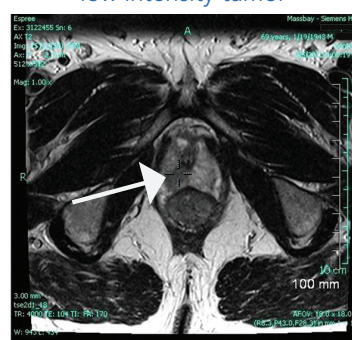
Patient information and preparation.

Compared with alternative tests that can be intrusive and painful, mpMRI is a standard MRI that requires no endorectal coil. The improved accuracy of tumor detection also potentially reduces the number of biopsies needed.

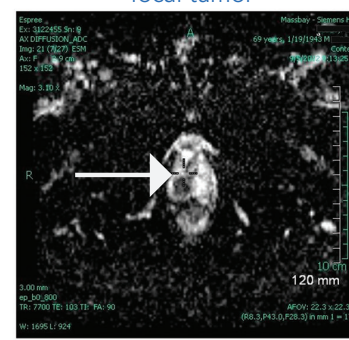
DCE shows focal tumor enhancement



T2 image shows focal low intensity tumor



Diffusion ADC map shows focal tumor



Tumor washout curve

